

ICM Case Summaries

a continuously expanding and updating free online educational resource for intensive care medicine professionals

[2013](#) / [3.6](#) / [4.1](#) / [6.1](#) / [7.2](#) / [ANATOMY](#) / [BASIC SCIENCES](#) / [CASE SUMMARY](#) / [DOMAIN 3](#) / [DOMAIN 4](#) / [DOMAIN 6](#) / [DOMAIN 7](#) / [NEUROMUSCULAR](#) / [PERIOPERATIVE](#) / [PHARMACOLOGY](#)

Post-operative Opioid-Induced Hyperalgesia

[JULY 4, 2016](#) [JULY 18, 2016](#) [ICM CASE SUMMARIES](#) [LEAVE A COMMENT](#)

An elderly female was admitted to the intensive care unit (ICU) following a planned hemi-hepatectomy to remove metastatic lesions from a previously resected primary colorectal cancer. The patient had declined neuraxial anaesthesia. The surgery proceeded uneventfully via a rooftop incision under general anaesthesia, which was maintained with remifentanyl, sevoflurane and paralysis with atracurium.

30 minutes before the termination of the three hour operation, a bolus of 10mg of morphine was given intravenously and a patient-controlled analgesia (PCA) morphine pump was prepared. At emergence from anaesthesia, paralysis was reversed, and the patient was successfully extubated. In the ICU the patient was instructed in the use of the PCA. She was initially comfortable, but within 30 minutes she complained of worsening abdominal pain around the upper abdominal incision and became tachycardic.

To address this patient's worsening post-operative abdominal pain 10mg of morphine was given intravenously. Simultaneously she was reassessed and the potential cause of the pain was sought. The abdomen remained soft and mildly tender. Drains were dry, and parameters including blood pressure, respiratory rate, haemoglobin, and arterial blood gases were satisfactory.

The morphine was ineffective. She was given 1g of intravenous paracetamol, a further bolus of 10mg of morphine and two sequential 500mL aliquots of crystalloid. Surgical review was requested. After another 20 minutes the pain had not diminished so she received a bolus of fentanyl and a trial dose of 100mg of intravenous tramadol. Unfortunately these measures did not reduce the pain at all. Although vital signs were unchanged, the patient was increasingly distressed.

There was no apparent clinical deterioration to account for the increased pain. Yet, control of her symptoms had clearly been lost and routine analgesia was ineffective. Urgent senior review was requested. Suspecting that she had become refractory to opioid analgesia, and concerned about the severity of the pain and its potential complications, the consultant stopped the patient's PCA, increased the inspired oxygen fraction to 0.80 through a non-rebreathe mask, and gave 50mg of ketamine intravenously.

These interventions significantly improved symptoms over the next ten minutes. The patient remained conscious though slightly drowsy and her tachycardia settled. Simple analgesics and a low dose infusion of 2-5 mcg/kg/min (approximately 10-25 mg/h) of ketamine were prescribed. These effectively controlled her pain. After the patient had remained comfortable and clinically stable for several hours, the PCA was gradually re-introduced and the ketamine was discontinued. She was discharged to the ward the following day.

What is opioid-induced hyperalgesia?

Joel Meyer

Opioids are the cornerstone of intra- and post-operative analgesia. When patients experience inadequate opioid analgesia despite effective doses, this is often explained by the development of tolerance. Although usually a problem associated with chronic opioid use, it also occurs acutely¹. It is usually overcome by increasing the dose.

Anaesthetists, intensive care physicians, and pain specialists are increasingly recognising a second phenomenon, called opioid-induced hyperalgesia (OIH), as a cause of acute failure of opioid analgesia². The international Association of the Study of Pain defines hyperalgesia as "an increased response to a stimulus which is normally painful"³. In other words, there is increased sensitivity to pain, rather than decreased sensitivity to analgesia (the latter being tolerance). Intra-operative remifentanil infusion is a common trigger.

Clinically, as in this patient, OIH manifests as uncontrolled pain and elevated post-operative pain scores. It is difficult to distinguish hyperalgesia from tolerance, and consequently the problem is often exacerbated by prescribing yet more opioids. Furthermore, both tolerance and hyperalgesia can probably co-exist³.

This dilemma has been partly eased by the recent insights into the pathophysiology of these conditions which reveals they are quite distinct. Tolerance happens by the desensitisation of anti-nociceptive mechanisms, such that a higher concentration of drug effector is required at the receptor. However in hyperalgesia, there is hypersensitisation of pro-nociceptive pathways by opioids⁴. Pharmacological overstimulation of pain receptors lowers the pain threshold.

A key mechanism in hyperalgesia appears to be mediated by the N-methyl-D-aspartate (NMDA) receptor, known for its major role in synaptic plasticity, and its agonist glutamate. Spinal neurones in culture exposed to remifentanil show increased NMDA receptor expression acutely⁵. Animal models of nociceptive pathways add further weight to the role of NMDA, with antagonists abolishing OIH hyperalgesia in mice undergoing an experimental fracture-pinning procedure with parenteral opioids⁶. This strengthens the rationale of using ketamine, an NMDA antagonist, in the management of OIH in humans.

hyperalgesia after laparotomy for colorectal surgery. 75 adults were randomised into three groups receiving anaesthesia with low dose remifentanyl, high dose remifentanyl, or high dose remifentanyl with ketamine. The ketamine was given as a loading dose just after induction and then a low maintenance infusion for 48 post-operative hours⁷.

The findings were a reduction in the post-operative tactile pain threshold and an increase in morphine requirements in the high dose remifentanyl group compared to the low dose. This difference was abolished by the addition of ketamine in the third group. The authors concluded that ketamine is effective at preventing OIH and also that the risk of remifentanyl causing OIH appears to be dose-dependent⁷.

Other studies have supported the claim that per-operative ketamine may be beneficial in preventing post-remifentanyl-infusion hyperalgesia⁸. However the reliability of the findings is often brought into doubt because human models of pain and hyperalgesia are complex and it is difficult to exclude confounding factors. Furthermore the outcome measures, including the visual analogue scale of pain, are subjective. Data on direct assessment of the effect of opioids on sensory thresholds are limited.

Laboratory studies have implicated several other endogenous neuropeptides, among them serotonin, dynorphin, cholecystokinin, substance P, and nitric oxide, in the pathogenesis of OIH. Ondansetron blocked signs of OIH in a mouse model of chronic pain through modulation of 5HT₃ in spinal cord dorsal horns⁹. Preoperative treatment with pregabalin prevented the pro-nociceptive effect of remifentanyl and propofol anaesthesia in 60 patients undergoing hysterectomy¹⁰. These may translate to effective future therapies for OIH.

The incidence of OIH remains unknown, and why some individuals are more at risk of OIH is not understood. The syndrome may turn out to be more than one clinical entity. Whether ketamine is effective as a rescue treatment for established OIH, not just as a prophylactic anti-hyperalgesic, has not been studied in controlled trials. However in this case a low dose infusion was effective at relieving the patient's discomfort and distress, both of which are known to adversely affect recovery after surgery.

Lessons learnt

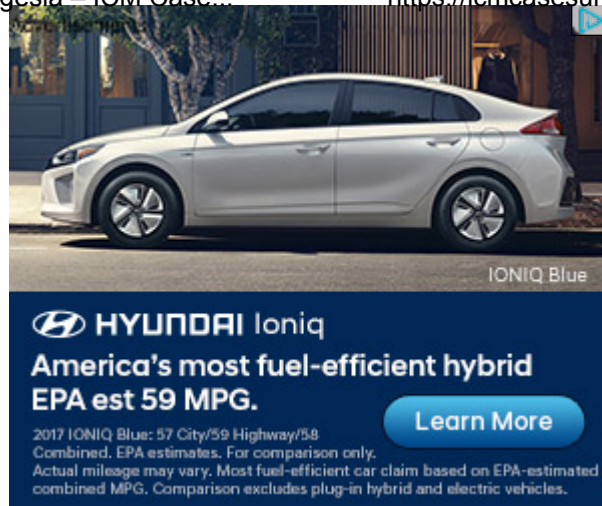
- It is important to be vigilant for opioid-unresponsive pain and consider the diagnosis of OIH.
- The present challenge facing clinicians is how to distinguish promptly between tolerance and hyperalgesia, two conditions requiring contrasting management, in the post-operative patient with uncontrolled pain.
- The dose of intra-operative remifentanyl may be an important determinant of remifentanyl induced hyperalgesia.
- Low dose ketamine infusion can be effective at treating established OIH in the ICU and ketamine should be considered per-operatively in patients known to be at risk of OIH.

References

1. Vinik HR, Kissin I. Rapid development of tolerance to analgesia during remifentanyl infusion in humans. *Anesth Analg* 1998;86:1307–11.

2. Mitra S. Opioid-induced hyperalgesia: pathophysiology and clinical implications. *J Opioid Manag* 2008;4(3):123-30.
3. Konopka KH, van Wijhe M. Opioid-induced hyperalgesia: pain hurts? *Br J Anaesth* 2010;105(5):555-7.
4. Trafton JA, Abbadie C, Marek K, Basbaum AI. Postsynaptic signaling via the [mu]-opioid receptor: responses of dorsal horn neurons to exogenous opioids and noxious stimulation. *J Neurosci* 2000;20(23):8578-84.
5. Zhao M, Joo DT. Enhancement of spinal N-methyl-D-aspartate receptor function by remifentanil action at delta-opioid receptors as a mechanism for acute opioid-induced hyperalgesia or tolerance. *Anesthesiology* 2008;109(2):308-17.
6. Minville V, Fourcade O, Girolami JP, Tack I. Opioid-induced hyperalgesia in a mice model of orthopaedic pain: preventive effect of ketamine. *Br J Anaesth* 2010;104(2):231-8.
7. Joly V, Richebe P, Guignard B, Fletcher D, Maurette P, Sessler DI, Chauvin M. Remifentanil-induced postoperative hyperalgesia and its prevention with small-dose ketamine. *Anesthesiology* 2005;103(1):147-55.
8. Koppert W, Sittl R, Scheuber K, Alsheimer M, Schmelz M, Schüttler J. Differential modulation of remifentanil-induced analgesia and postinfusion hyperalgesia by S-ketamine and clonidine in humans. *Anesthesiology* 2003;99(1):152-9.
9. Colvin LA, Fallon MT. Opioid-induced hyperalgesia: a clinical challenge. *Br J Anaesth* 2010;104(2):125-7.
10. Jo HR, Chae YK, Kim YH, Chai HS, Lee WK, Choi SS, Min JH, Choi IG, Choi YS. Remifentanil-induced pronociceptive effect and its prevention with pregabalin. *Korean J Anesthesiol* 2011;60(3):198-204.

□



HELPING YOU
BUY, BUILD
AND RESTORE

QUARTEX®
Q-80 QUARTZ

[VIEW SITE](#)



□ [JOEL MEYER](#)

[CREATE A FREE WEBSITE OR BLOG AT WORDPRESS.COM.](#)

