

See discussions, stats, and author profiles for this publication at: <https://www.researchgate.net/publication/285725073>

ON THE VARIATIONS OF CERVICAL DERMATOMES

Article *in* International Journal of Anatomy and Research · September 2014

READS

15

2 authors, including:



[Henrietta Nittby](#)

Lund University

38 PUBLICATIONS 393 CITATIONS

SEE PROFILE

ON THE VARIATIONS OF CERVICAL DERMATOMES

Henrietta Redebrandt Nittby, MD, PhD ^{*1,2}, Tom Bendix, MD, Dr Med Sci ¹.

^{*1} Center for Rheumatology and Spinal Diseases, Glostrup Hospital, University of Copenhagen, Glostrup, Denmark.

² Department of Neurosurgery, Skåne University Hospital, Lund University, Sweden.

ABSTRACT

Background: Nerve-root related dermatomes have been considered to have quite solid anatomical framings. However, especially in the lumbar region, studies have questioned such firm anatomy. Regarding the cervical nerve roots, many studies have shown an overlap between different dermatomes, which of course affects decisions taken in the clinical work. All the same, dermatome drawings with clear borders are still widely used.

Context and purpose of the study: We conducted a literature review in order to find today's state of the art, including the methods on which the anatomical atlases have been based. The overall pragmatic thoughts were to create summarized guide for clinicians when trying to correlate an MRI-demonstrated prolapse/recess stenosis to pain and neurologic findings, particularly if the nerve root's peripheral neurology does not follow conventional anatomy.

Results: We isolated 24 studies that sufficiently dealt with the issue of cervical dermatomes. Pain and sensory disturbance caused by cervical root affection could deviate from the dermatomal patterns. We found indications that sometimes no paralysis or anaesthesia would be seen after section of a single root. Because the fraction of cases without classical fit between nerve root and anatomical level cannot be given, studies should go into this issue.

Conclusion: There are many studies showing that dermatomal distributions are varying, and not only overlapping. We therefore mean that new studies, with modern imaging and surgical techniques, are much needed.

KEYWORDS: Cervical nerve root, dermatome, radicular pain, radiculopathy.

Address for Correspondence: Henrietta Nittby, MD, Department of Neurosurgery, Skåne University Hospital, Lund University, Sweden, BMC D10 SE-221 85 Sweden.

E-Mail : henrietta.nittby@med.lu.se

Access this Article online

Quick Response code



Web site: International Journal of Anatomy and Research
ISSN 2321-4287
www.ijmhr.org/ijar.htm

Received: 17 June 2014

Peer Review: 17 June 2014 Published (O):31 July 2014

Accepted: 07 July 2014 Published (P):30 Sep 2014

INTRODUCTION

According to the Oxford dictionaries, a dermatome is "an area of the skin supplied by nerves from a single spinal root". During the 19th and 20th centuries, the establishment of dermatomes and anatomical studies attracted focus. Interestingly, in some studies, it was presented that there was an overlap of the dermatomal patterns as well. In the latter parts of the 20th century, this was further investigated through root stimulations, either with blockades or pain provocation, when trying to define the

correct root for surgical intervention. However, in recent years, interest in this field seems to have faded. A search for 'dermatome' at e.g. the American Association for Anatomists only gave one hit. Yet, the understanding of sensory innervation and dermatome distributions and variations is pivotal in clinical work. It should be noted that understanding the overlap is important, but it is even more practically relevant to try to identify the following: What is the main location of pain and hypesthesia following a certain nerve root affection? During recent

years, but also from the beginning of the last century, the overlap between different dermatomal levels has been described repeatedly. Nevertheless, standardised dermatomal maps with linear borders are still used in text books. Therefore, the aim was to perform a review on available studies of anatomical locations of cervical derma- and myotomes' overlap, and cervical-level variations from those traditionally believed.

MATERIALS AND METHODS

We designed our study in order to identify current articles covering the issue of cervical dermatome locations. A PubMed search was performed, with the words "cervical" and "dermatome". From the articles found, the relevant ones were sorted out by reviewing either title or, when in doubt, also abstracts. In order to be able to cover in a larger number of articles than those found in a PubMed search, and above all those original works from the beginning of the 19th century and start of the 20th century, also references from those articles selected in the PubMed search were considered.

RESULTS

PubMed search

A PubMed search including the words "cervical dermatome" gave 183 hits (2014 March 20th), ten of them (Ladak et al. 2013; [Murphy et al. 2009](#); [Anderberg et al. 2006](#); [Poletti 1991 and 1996](#); [Kasai et al. 1989](#); [van Kleef et al. 1993](#); [Keegan 1947](#), [Pop et al. 1989](#) and [Ash et al. 1986](#)) were focusing more directly upon the dermatomes and their anatomical distributions, as selected by title and abstract (see Figure 1). The reference lists of the articles were considered, and as selected by title and abstract another 14 relevant papers were defined. For a summary, see Table 1.

Results presented in chronological order

Older studies from the end of the 19th and start of the 20th centuries – including dissection studies

[1] Initial studies, suggesting the presence of dermatomes, were carried out by Sir Charles Sherrington at the end of the 19th century (1893). Experiments were performed on the rhesus monkeys, where he isolated single roots by cutting some of the roots above and below. He

then determined the area where pain sensation remained, and suggested that this would correspond to dermatomes.

[2] Sir Henry Head and Campbell (1900) studied 21 patients with herpes zoster, which is supposed to affect the dorsal spinal ganglia and give rise to eruptions in the skin. His dermatomal patterns based upon this showed little overlap. Both cervical, thoracic and lumbar dermatomes were examined. Ten levels were examined post-mortem and found to be correctly numbered, but regarding the cervical levels only the 3rd and 4th were examined in this way. Interestingly, the authors wrote: "We are also confronted with another difficulty which must always make such a combined diagram incomplete; for the supply of the afferent ganglionic fibers is subject to variation, and any one portion of skin may be supplied in the one patient by the fibers that enter one ganglion, in another by those that enter the ganglion above or below."

[3] Bolk at the start of the 20th century (cited in [Nieuwenhuys 1975](#)) carried out dissections of peripheral nerves, through their plexus and to the spinal roots. He meant that the spinal nerves represented their original spinal segments. He presented drawings showing that the dermatomes corresponded to successive spinal nerves and meant that: "in principle, each segment encompasses a part of all organ systems: it is therefore possible to distinguish a dermatome, a myotome, a sclerotome, a neurotome, a vasotome and a viscerotome or splanchnotome."

[4] Albert Kerr in 1918 presented a summary of cadaver dissections, where peripheral nerves had been dissected and followed, resulting in 400-500 diagrams, from which 175 were chosen. These 175 diagrams were evaluated by the author as scientifically correct. The anterior rami entering the brachial plexus were recorded. It was found that the number of cephalic nerves entering the plexus varied. This meant that in some cases the 4th cervical root joined the plexus (63%), in some cases the cephalic limitation was the 5th cervical root (30%) and finally, sometimes only a part of the 5th cervical root was included (7%).

[5] In 1933, Foerster made a thorough summary

Table 1: Studies included in this review of cervical dermatomal distributions.

Number/author	Materials	Test of root affection / stimulation.	n =	Results
[1] Sherrington 1893	Living monkeys	Cutting nerve roots above and below	17	Suggested presence of dermatomes.
[2] Head 1900	Ptt/10 levels dissected post-mortem	Herpes zoster localization	21	Little overlap between dermatomes, varying afferent communication to ganglion.
[3] Bolk start 20 th century, later described by N Nieuwenhuys	Cadavers	Peripheral nerves	1	Dermatomes corresponded to successive spinal nerves, possible to distinguish dermatome /myotome /viscerotome.
[4] Kerr 1918	Cadavers	Peripheral nerves	175	Number of cephalic nerves entering the brachial plexus varied.
[5] Forester 1933	Division of continuous roots in patients during surgery	Electrical stimulation	Not specified	Large overlap of the dermatomes, Resection of one root gave no sensibility defects.
[6] Freeman 1935	Ptt/ examples of sectioning thoracic roots	-	2	Overlap of spinal roots explained why no paralysis or anaesthesia would be seen after section of a single root.
[7] Keegan 1947	11 ptt / operated	-	51 clinical cases	Definitive dermatome area of hypalgesia for the 4 th , 5 th , 6 th , 7 th and 8 th cervical nerve roots each.
[8] Schwartz 1956	Cadavers /dissected	-	13	Anastomotic rami between adjacent sensory roots were found in all objects at different magnitude, most frequent between C6-C7.
[9] Dykes & Terzis 1981	Living African green monkeys	Laminectomy C2-T6, dissection of dorsal roots,	10	Variation of the cutaneous regions supplied by one spinal nerve; myotome does not always coincide with the dermatome. Any point of skin supplied by at least three dermatomes.
[10] Perneckzy & Sunder-Plassmann 1982	Cadavers /dissection	-	40	Intradural communicating fibres between neighbouring segments.
[11] Ash et al. 1986	Ptt	Thermography	87 patients and 31 controls	In no case could correlation be made between temperature change and a proven neurologic deficit.
[12] Marzo 1987	Cadavers / dissected	-	54	Communicants between the dorsal roots in 53 of the 54 spines.
[13] Pop et al. 1988	Ptt/ cortical evoked potentials	Dermatomal stimulation (SEP)	35 volunteers	No correlation between mean latency between SEP and cortical evoked potentials and body length for cervical dermatomes (but for lumbosacral). No discussion about dermatomes as such.
[14] Kasai et al. 1989	Cadavers / dissected	- Human dorsal roots	31	Most frequently it was observed that the dorsal rami from the 6 th , 7 th and 8 th cervical levels failed to develop cutaneous branches.
[15] Poletti 1991	Ptt.	Surgical decompression/ rhizotomy/electrical root stimulation/anaesthetic root block	17 ptt, 8operated	Description of findings of C2 and C3 dermatomes. Overlap was seen in the suboccipital region in some cases.
[16] Poletti 1996	Cadavers and 6 ptt	Surgical decompression	5 cadavers, 6 operated patients	C3 nerve root and ganglion compression, although uncommon, does occur.
[17] van Kleef 1993	Patients / Rhizotomy	Guided by diagnostic segmental nerve blocks under fluoroscopy	20 patients	There was a reduction in pain score after surgery, but the correlation between affected nerve root and dermatomal pain distribution was not discussed.
[18] Slipman et al. 1998	Ptt	Nerve root block	87 patients	Dermatomal maps were created for each nerve root. It was found that in "a relatively high percentage" the radicular pain did not fall within expected dermatomes.
[19] Anderberg et al. 2004	Ptt	SNRB	20	It was found that in 14 out of 20 patients, the clinical presentation "did not fully reveal which nerve root was 'guilty'".
[20] Anderberg et al. 2006	Ptt	SNRB	30	SNRB correlated to the most degenerated level on MRI in 17 of 30 patients, radicular pain distribution according to the classical dermatomes in 7 out of 30 patients, and to the level decided by neurological deficits (defined as "motor strength and/or sensory deficit and/or changes in tendon reflexes") in 8 out of 30 patients
[21] Goldstein 2002	Ptt	Goal to describe applied anatomy of nerve root, not defined how papers were selected	33 articles, also including lumbar spine	Review: that no definitive study within the field was at hand. Concluded that frequently the symptoms of radiculopathy did not correspond to the expected anatomical patterns.
[22] Murphy 2009	Ptt/ Clinical examination, MRI/CT/EMG	Nerve root provocation tests	94 cervical nerve roots	In 69% of all 94 cases of cervical nerve root associated pain, the pain was non-dermatomal.
[23] Cardiri 2011	Ptt	-	84 articles defined by PubMed search	Review of indications for surgery, without referring to patient variations between individuals regarding the distribution of the cervical dermatomes.
[24] Ladak 2013	Ptt/nerve communications, including upper extremity	-	10 articles regarding upper extremity defined by Pub Med/ Google/ Ovid Medline search	Made maps reviewing previous literature: overlap was found from all major peripheral nerves, but they had to be contained within so called axial lines. Axial lines were separated from dermatomal lines.

of dermatomal research up to that date. A dermatome was defined as “the area of skin which is supplied by the fibres of a certain spinal root”. It could be defined through anatomy or physiology. A drawback with the anatomical method was meant to be that the last ramifications of the distal nerve fibres could not be followed. As physiological methods strychnine intoxication of the posterior roots was mentioned, and the author referred to a study by Dusser de Barenne, where hyperaesthetic areas were defined and a large degree of overlap of dermatomes adjacent to each other was observed. It was also referred back to work by Sir Henry Head, who made dermatomal studies based upon herpetic lesions and found out that there was almost no overlap of the dermatomes. Thus, already at that time, there was a discussion about dermatomal overlap and correlation to the nerve roots. Foerster himself contributed with knowledge within the area by presenting cases where contiguous roots were divided and a single root in the middle was left intact, during which the border of sensibility was defined. This was the case for all lumbar roots and for the 6th and 2nd cervical roots. Other cervical roots were electrically stimulated and vasodilatation was observed. Pictures of the patients and the dermatomal patterns pictured on them were presented. Problems were that neither was the variation between subjects fully described, nor exactly how many patients who were actually included in the study. Foerster came to the conclusion that there was a large overlap of the dermatomes, and that resection of one root gave no sensibility defects.

[6] In 1935, Freeman debated that overlap of spinal roots explained why no paralysis or anaesthesia would be seen after section of a single root. He wrote that: “It has been known for a long time that section of a single spinal root is followed by neither paralysis nor sensory loss of any importance, but that cutting of two adjacent roots is followed by such loss.” He further meant that the division between adjacent segments should be made between the upper and lower points of each two adjacent roots at each level. He concluded that this was the reason that there was neither total paralysis nor sensory loss from damaging just one single

root. Regarding dorsal nerve roots, he also commented upon the fact that the anaesthesia resulting from cutting two adjacent nerve roots would show substantial variation, possibly due to even more nerve roots contributing the innervation. As an example, it was mentioned that cutting the 10th and 11th thoracic dorsal roots resulted in an irregular anaesthetic band. As compared to the varying segmentation of the dorsal roots, the segmentation of the spinal cord itself was concluded to be much more stable over subjects.

[7] Keegan and Garrett reported in 1947 51 clinical cases with, what they considered a definitive dermatome area of hypalgesia for the 4th, 5th, 6th, 7th and 8th cervical nerve roots each, where the anamnesis indicated cervical disc herniation. They meant that unilateral herniation of a cervical disc resulted in affection of only one nerve root and therefore sensory and motor loss would be seen only in the distribution of that nerve root. However, only 11 of the 51 cervical cases were operated, and therefore the remaining cases could not be considered to be definitely confirmed.

[8] In 1956, Schwartz could explain that pain and sensory disturbance caused by cervical root affection could deviate from the dermatomal patterns. Thirteen human bodies were dissected and anastomotic rami between adjacent sensory roots were found in all objects at different magnitude. Approximate bilateral symmetry of the anastomoses was noted in only one of the cases. The most frequent communications were found to be between C6 and C7 roots. Most anastomoses came from the ganglion of the nerve below, and joined the fibres from the segment one level above. Interestingly, Schwartz also referred back to studies made already at the beginning of the 20th century by Kazzander and Weigner, where similar anastomoses at the cervical level were observed.

Studies from the later part of the 20th century – including monkey studies and more recent dissection studies

[9] In 1981 Dykes and Terzis reported the results of terminal experiments on 10 African green monkeys, where single nerve fibres from the dorsal cervical nerve roots were dissected. It was found that there was a variation of the cutaneous.

regions supplied by one spinal nerve and the myotome did not necessarily coincide with the dermatome from the same level.

[10] Pernecky and Sunder-Plassmann reported in 1980 the examinations of 40 post-mortem specimens of the cervical posterior roots under surgical microscope. Intradural communicating fibres between neighbouring segments were demonstrated. It was concluded that the exact localization of nerve root compression is hampered by variations, and that there are implications of the frequent variants for the diagnosis of prolapsed cervical discs. "In all of the 40 specimens at least one intradural variant of the cervical posterior roots was found to be present. Two and more variants of sensory roots were demonstrable in 33 specimens." It was predominantly the posterior roots of C4 and C7 which were involved in these variants.

[11] Ash et al. (1986) concluded that thermographic imaging of the sensory dermatome was not plausible, but dwelled no further upon the sensory dermatomes more specifically.

[12] Marzo et al. (1987) dissected 54 human cervical spines, and found communicants between the dorsal roots in 53 of the 54 spines. It was suggested that this might provide an overlap between the sensory dermatomes.

[13] Pop et al. (1988) investigated cortical evoked potentials after dermatomal stimulation (SEP). Cervical recordings were made in 35 volunteers. Latency time between peripheral stimulation and cortical evoked response were measured. However, they did not discuss dermatomal distribution as such, but instead it was presumed that this did not vary across the subjects.

[14] Kasai et al. (1989) investigated the cutaneous branches from the cervical dorsal roots in 31 human cadavers, dissected on both sides except for one case. In 60 out of 61 cases it was found that there was absence of cutaneous branches from the dorsal rami, regarding the lower cervical nerves. In 87% of the cases the cutaneous branches were absent in successive segments. Most frequently it was observed that the dorsal rami from the 6th, 7th and 8th cervical levels failed to develop cutaneous branches. They meant that only in 2% of all cases, dermatomal maps such as that

presented by Keegan and Garret in 1948, were relevant. In the majority of the cases, some segments of the lower cervical dorsal rami lacked cutaneous branches.

[15] Poletti (1991) and [16] (1996) focused upon C2 and C3 dermatomes and their distributions. In the study from 1991, six patients microsurgically treated with decompression of C2 or C3 nerve roots were included. The authors presented a description of their findings of C2 and C3 dermatomes. Overlap was seen in the suboccipital region in some cases. In the study from 1996, Poletti et al described C3 nerve root compression, and meant that this might lead to radiating pain, dysesthesia, numbness and C3 dermatome sensory deficit, which resolved after facetectomy.

[17] van Kleef et al. (1993) studied 20 patients with cervical pain radiating to the head/shoulder/arm for at least 1 year. Diagnostic segmental nerve blocks under fluoroscopy were performed at all levels which were estimated to be relevant either through localisation of the pain or findings on physical examination. The level with the best analgetic response was chosen for RF rhizotomy. There was a reduction in pain score after the procedure, but the correlation between affected nerve root and dermatomal pain distribution was not discussed. Most recent studies including nerve-root stimulation

[18] Slipman et al (1998) investigated the correlation between cervical nerve root pain and classic sensory dermatome in 87 patients with cervical radicular symptoms at C4 to C8. The definition of cervical radicular symptoms was "pain that radiated through the upper extremity distal to the elbow", and these symptoms could be reproduced with Spurling's test or root tension manoeuvres. The cervical nerve root defined by the examination was stimulated with a needle between contrast injection and contrast and local anaesthetic injection, only one nerve root at a time. Dermatomal maps were created for each nerve root. It was found that in "a relatively high percentage" the radicular pain did not fall within expected dermatomes. However, statistical analyses of the percentage that did not match dermatomal patterns were

not presented. It was said that all subjects had a cervical MRI performed before testing, but the correlations between the MRI findings and the pain provocations by diagnostic SNRB (selective diagnostic nerve root blocks) were not presented further.

[19] [Anderberg et al. \(2004\)](#) investigated the effects of SNRB, in 20 patients with cervical radiculopathy and single level MRI pathological findings (soft discs and/or spondylosis at the same side as the radicular pain). It was found that in 14 out of 20 patients, the clinical presentation “did not fully reveal which nerve root was ‘guilty’”, but the analyses are not statistically explored in more detail and the exact way of the clinical examinations performed were not presented. They concluded from the study that SNRB could be a useful tool in identifying the clinically significant root.

[20] A few years later, [Anderberg et al \(2006\)](#) presented a prospective study in order to correlate transforaminal SNRB to clinical symptoms and MRI findings in 30 patients with degenerative disease in the cervical spine at two levels, and outcome depending on nerve block treatment with steroid injections, surgery or conservative treatment. Degeneration on MRI findings was graded by the reduction of the area of the neuroforamen; the cause of reduction was not specified. It was described that the patients were examined by neurosurgeon after MRI, which seems to imply that the neurosurgeon already had a MRI answer when making the clinical examination. **The primary finding was that 18 patients had effect of SNRB on a single level, and 11 had effects of SNRB on two levels. Interestingly, it was also found that SNRB correlated to the most degenerated level on MRI in 17 of 30 patients, radicular pain distribution according to the classical dermatomes in 7 out of 30 patients, and to the level decided by neurological deficits (defined as “motor strength and/or sensory deficit and/or changes in tendon reflexes”) in 8 out of 30 patients.** The possible/likely(?) bias was not discussed. The level decided by neurological deficits correlated to MRI findings in 15 out of 30 patients, and of these 15 only 6 correlated to the SNRB.

[21] [Goldstein \(2002\)](#) described in a review how dermatomes are not separated sharply, based

upon animal studies, but also anatomical studies and different studies based upon neurological lesions. However, he meant that no definitive study within the field was at hand. He also referred to previous studies, where intradural communicants between adjacent cervical spinal roots have been shown ([Freeman et al. 1935](#) and [Marzo et al. 1987](#)). Goldstein **concluded that frequently the symptoms of radiculopathy did not correspond to the expected anatomical patterns, which is due to the common variations of nerve roots and spinal nerves,** which were not least differing much between individuals.

[22] [Murphy et al. \(2009\)](#) questioned whether radicular pain necessarily followed a specific dermatome. Patients were chosen at a spine centre, and considered to fulfil the criteria of radicular pain. **They assessed 94 MR/CT defined cervical nerve roots, affected by disk protrusions and/or lateral canal stenosis or with EMG documentation of nerve root dysfunction together with nerve root provocation tests. “For a pain pattern to be deemed dermatomal, the pain must be contained within the area designated in the reference sources as arising from the nerve root involved. If all or part of the pain pattern fell outside the area designated by both reference sources for the involved nerve root, it was designated non-dermatomal.”** Regarding specific nerve root levels, the majority of affected roots followed a non-dermatomal pattern of radiculopathy for the levels C5, C6, C7. For the C4 level, the majority of the affected roots led to a dermatomal pattern of radiculopathy. This meant that in 69% of all 94 cases of cervical nerve-root associated pain, the pain was non-dermatomal. It was suggested that overlap between dermatomes could explain this finding, but another hypothesis presented was that there might be other sources of pain, such as intervertebral discs or the dura mater.

[23] In a review [Caridi et al. \(2011\)](#) described cervical radiculopathy and the suggested diagnostic tools. It is described that “the clinical consequence of radiculopathy is arm pain or paresthesia in the dermatomal distribution of the affected nerve and may or may not be associated with neck pain and motor weakness”. This was done without referring to patient variations between individuals regarding the

distribution of the cervical dermatomes, and actually was underlining the general perception that specific peripheral symptoms directly refer to a specific cervical root.

[24] Ladak et al. (2013) described in a review the knowledge of peripheral nerve overlap. In the head and neck region, the overlap was found from all major peripheral nerves, but they had to be contained within so called axial lines - i.e: "lines formed where non-contiguous spinal nerves meet, across which minimal to no sensory overlap occurs". That is, the axial lines should be separated from dermatomal lines, and between different axial lines no sensory overlap existed. In the upper extremity, axial lines were present on the anterior and posterior surfaces of the arm separating the C5-C6 and T1-2 dermatomes, only the proximal part of the arm was considered to have axial lines, and thus there was no axial line separating for example C7 dermatome from C6 dermatome or C8 dermatome. The conclusion was that "within axial line territories, in areas of sensory dermatome overlap, there often also exist physical communications between nerves derived from contiguous spinal nerves". Based upon this, a map showing these overlaps was suggested. It was suggested to be contained within an axial line theory, but also embryologically explainable: "dermatome distribution is affected by longitudinal growth of the limbs as the cutaneous sensory nerves elongate toward their targets".

Fig. 1: Result of pub med search for cervical dermatome.

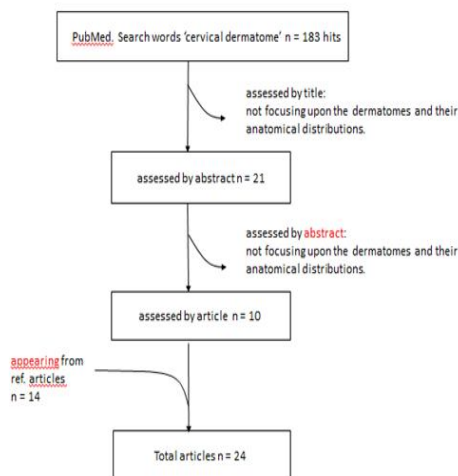
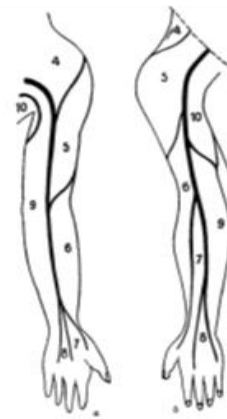

Fig. 2: From Nieuwenhuys (1975), original drawing by Bolk, showing his pictures of the arrangements of dermatomes in the upper extremity, as suggested by Bolk from his dissection studies.



DISCUSSION AND CONCLUSION

The anatomy of cervical spinal nerves is well established. Knowledge of the normal supply and draining areas of these nerve roots, and the pathology associated with impingement, is helpful when trying to diagnose radiculopathy in many cases. However, frequently the symptoms and clinical observations do not correlate with expected anatomical patterns. Commonly, variations of nerve roots and their connections with each other, lead to another picture. Dermatome maps used today are based upon studies with different methods, and many studies also lack a detailed presentation of the material and methods used as a basis for their conclusions. As with so many other parts of anatomy and physiology, there are inter-individual variations that need to be taken into account during daily clinical decisions.

Though a vast amount of anatomical and physiological research has been done on patients, cadavers and animals, there seems to be lack of knowledge of how often an affection of a specific root should give rise to symptoms within its specific dermatome, and how often this dermatome fits or does not fit into classical anatomy.

Therefore, our main conclusion is that the clinical symptoms of cervical nerve root affections should be interpreted very carefully, and today, now that advanced neuro-radiological examination methods are at hand, it would be highly interesting to complete many of the old anatomical studies with new evidence and, if

possible, also use the knowledge found by surgical interventions. Moreover, we think that it is important to keep in mind that there, during the years, has been increasing evidence of a vast variation between individuals, indicating that pre-designed dermatomal maps should be handled carefully.

Conflicts of Interests: None

ACKNOWLEDGEMENTS

We are thankful to Anders Føhrby Overgaard for initial contribution with conception of the study.

REFERENCES

- [1]. Sherington CS. Experiments in examination of the peripheral distribution of the fibres of the posterior roots of some spinal nerves. *Phil Trans Roy Soc London, series B* 1893; 184: 641-763.
- [2]. Head H and Campbell AW. The pathology of herpes zoster and its bearing on sensory localization. *Brain* 1900; 23:353.
- [3]. Nieuwenhuys. Bolk's studies on segmental anatomy. *Acta Morphol Neerl.-Cand.* 1975; 13: 7-33.
- [4]. Kerr A. The brachial plexus of nerves in man, the variations in its formations and branches. *The American journal of anatomy* 1918; 23(2) 285-395.
- [5]. Foerster O. The dermatomes in man. *Brain* 1933; 1(56): 1-36.
- [6]. Freeman W. Motor and sensory overlap in the spinal roots. *Ann Surg* 1935; 101:133-7.
- [7]. Keegan JK. Dermatome hypalgesia with posterolateral herniation of lower cervical intervertebral disc. *J Neurosurg* 1947; 4(2):115-39.
- [8]. Schwartz HG. Anastomoses between cervical nerve roots. *Neurosurgery* 1956; 13:190-4.
- [9]. Dykes RW and Terzis JK. Spinal nerve distributions in the upper limb: the organization of the dermatome and afferent myotome. *Philos Trans R Soc Lond B Biol Sci* 1981; 293(1070): 509-54.
- [10]. Perneczky A and Sunder-Plassmann M. Intradural variant of cervical nerve root fibres potential cause of misinterpreting the segmental location of cervical disc prolapses from clinical evidence. *Acta Neurochir* 1980; 52(1-2): 79-83.
- [11]. Ash CJ, Shealy CN, Young PA, Van Beaumont W. Thermography and the sensory dermatome. *Skeletal Radiol.* 1986; 15(1):40-6.
- [12]. Marzo JM, Simmons EH, Kallen F. Intradural connections between adjacent cervical spinal roots. *Spine* 1987; 12(10):964-68.
- [13]. Pop PH, Oepkes CT, Notermans SL, Vlek NM, Stegeman DF. Dermatomal somatosensory evoked potentials of the lumbar and cervical roots. Method and normal values. *Eur Arch Psychiatry Neurol Sci.* 1988; 238(1):22-7.
- [14]. Kasai T, Chiba S, Suzuki T, Okuno Y. Cutaneous branches from the dorsal rami of the cervical nerves, with emphasis on their positional relations to the semispinalis cervicis. *Okajimas Folia Anat Jpn.* 1989; 66(4):153-9.
- [15]. Poletti CE. Third cervical nerve root and ganglion compression: clinical syndrome, surgical anatomy, and pathological findings. *Neurosurgery.* 1996; 39(5):941-8.
- [16]. Poletti CE. C2 and C3 pain dermatomes in man. *Cephalalgia.* 1991; 11(3):155-9.
- [17]. Van Kleef M, Spaans F, Dingemans W, Barendse GA, Floor E, Sluifster ME. Effects and side effects of a percutaneous thermal lesion of the dorsal root ganglion in patients with cervical pain syndrome. *Pain.* 1993; 52(1):49-53.
- [18]. Slipman CW, Plasteras CT, Palmitier RA, Huston CW, Sterenfeld EB. Symptom provocation of fluoroscopically guided cervical nerve root stimulation. A redynamical maps identical to dermatomal maps? *Spine.* 1998; 15(23):2235-2242
- [19]. Anderberg L, Annertz M, Brandt L, Saveland H. Selective diagnostic cervical nerve root block – correlation with clinical symptoms and MRI-pathology. *Acta Neurochir (Wien)* 2004; 146: 559-565.
- [20]. Anderberg L, Annertz M, Rydholm U, Brandt L, Saveland H. Selective diagnostic nerve root block for the evaluation of radicular pain in the multilevel degenerated cervical spine. *Eur Spine J.* 2006; 15:794-801.
- [21]. Goldstein B. Anatomic issues related to cervical and lumbosacral radiculopathy. *Phys Med Rehabil Clin N Am* 13 2002; 423-437.
- [22]. Murphy DR, Hurwitz EL, Gerrard JK, Clary R. Pain patterns and descriptions in patients with radicular pain: does the pain necessarily follow a specific dermatome? *Chiropr Osteopat* (2009) 17:1-9.
- [23]. Caridi JM, Pumberger M, Hughes AP. Cervical Radiculopathy: A Review. *HSSJ* 2011; 7:265-272.
- [24]. Ladak A, Tubbs RS, Spinner RJ. Mapping Sensory Nerve Communications Between Peripheral Nerve Territories (2013). *Clinical Anatomy e-pub ahead of print.*

How to cite this article:

Henrietta Redebrandt Nittby, MD, PhD, Tom Bendix, MD, Dr Med Sci. ON THE VARIATIONS OF CERVICAL DERMATOMES: A REVIEW. *Int J Anat Res* 2014;2(3):462-69.