

Case Report

Successful Treatment of Meralgia Paresthetica with Pulsed Radiofrequency of the Lateral Femoral Cutaneous Nerve

Cyril N. Philip, MD, Kenneth D. Candido, MD, Ninos J. Joseph, BS, and George J. Crystal, PhD

From: Advocate Illinois Masonic Medical Center, Chicago, IL.

Dr. Philip is a Resident Physician, Department of Anesthesiology and Pain Management, Advocate Illinois Masonic Medical Center, Chicago, IL. Dr. Candido is Chair, Department of Anesthesiology and Pain Management, Advocate Illinois Masonic Medical Center and Clinical Professor of Anesthesiology, University of Illinois College of Medicine, Chicago, IL. Joseph is a Research Associate, Department of Anesthesiology and Pain Management, Advocate Illinois Masonic Medical Center, Chicago, IL. Dr. Crystal is Director of Research Laboratory, Department of Anesthesiology and Pain Management, Advocate Illinois Masonic Medical Center and Professor of Anesthesiology, University of Illinois College of Medicine, Chicago, IL.

Address correspondence:
Kenneth D. Candido, MD
Chair, Department of Anesthesiology
and Pain Management
Advocate Illinois Masonic Medical Center
836 W. Wellington Avenue
Chicago, IL 60657.
E-mail: kdcandido@yahoo.com

Disclaimer: Presented as a Medically Challenging Case at the Annual Meeting of the American Society of Anesthesiologists, October 18–22, 2008, Orlando, FL
Conflict of interest: None.

Manuscript received: 01/16/2009
Revised manuscript received: 03/05/2009
Accepted for publication: 04/02/2009

Free full manuscript:
www.painphysicianjournal.com

Background: Meralgia paresthetica is a rarely encountered sensory mononeuropathy characterized by paresthesia, pain or sensory impairment along the distribution of the lateral femoral cutaneous nerve caused by entrapment or compression of the nerve as it crosses the anterior superior iliac spine and runs beneath the inguinal ligament.

Objective: We describe the first reported use of pulsed radiofrequency neuromodulation to relieve the intractable pain associated with meralgia paresthetica.

Case Report: A 33-year-old morbidly obese female with a history of lower back pain and previous spinal fusion presented with sensory dysesthesias and paresthesias in the right anterolateral thigh, consistent with meralgia paresthetica. Temporary relief occurred with multiple lateral femoral cutaneous nerve and fascia lata blocks at 2 different institutions. The patient expressed dissatisfaction with her previous treatments and requested “any” therapeutic intervention that might lead to long-lasting pain relief. At this time, we located the anterior superior iliac spine and reproduced concordant dysesthesia. Pulsed radiofrequency was then undertaken at 42°C for 120 seconds followed by dexamethasone and bupivacaine. The patient reported exceptional and prolonged pain relief at 6-month follow-up.

Limitations: Since this case report is not a prospective, randomized, controlled or blinded study, no conclusions may be drawn from the results attained on behalf of this single individual. Additional, larger group analyses studying this technique while eliminating bias from patient variables would be essential prior to assuming any validity to using pulsed radiofrequency techniques of neuromodulation for managing peripheral neuropathic pain processes.

Conclusion: The patient had experienced long-standing pain that was recalcitrant to conservative/pharmacologic therapy and multiple nerve blocks with local steroid instillations. A single treatment with pulsed radiofrequency resulted in complete and sustained cessation of pain. No side effects were evident. Pulsed radiofrequency of the LFCN may offer an effective, low risk treatment in patients with meralgia paresthetica who are refractory to conservative medical management or are unwilling or unfit to undergo surgery.

Key words: Meralgia paresthetica, pulsed radiofrequency, lateral femoral cutaneous nerve

Pain Physician 2009; 12:881-885

Meralgia paresthetica, also termed Bernhardt-Roth syndrome, is a rarely encountered (4.3 cases per 10,000 person-years) (1) sensory mononeuropathy. This condition is characterized by paresthesia, pain, or sensory impairment along the distribution of the lateral femoral cutaneous nerve (LFCN) caused by entrapment or compression of the nerve as it crosses the anterior superior iliac spine and runs beneath the inguinal ligament to enter the thigh. Most patients with meralgia paresthetica achieve satisfactory pain relief from conservative treatment modalities, such as lifestyle changes, weight loss, and the administration of analgesic and anti-inflammatory drugs, or from single/multiple therapeutic local anesthetic nerve blocks. However, a small group of patients demonstrate intractable pain that is refractory to these treatments. In such cases, more aggressive interventions have been considered, including surgical decompression (neurolysis) or transection of the LFCN (2).

Radiofrequency signals have been used for many years to block pain transmission (3). The conventional use of these procedures involves a continuous application of high temperature, which may be associated with Wallerian degeneration, severe neurodestruction, and a deafferentation effect (4,5). Pulsed radiofrequency is an alternative to continuous radiofrequency, and appears to be relatively free of tissue damaging effects (6). Pulsed radiofrequency has been used successfully for the treatment of a wide variety of neuropathic pain syndromes, including monoradiculopathies (7,8), trigeminal neuralgia (9), postherpetic neuralgia (10), phantom limb pain (11), chronic post-surgical thoracic pain, and peripheral neuropathies (6,12). This case report describes the first reported use of pulsed radiofrequency neuromodulation to relieve the intractable pain associated with meralgia paresthetica that was refractory to more conservative treatment modalities.

REPORT OF A CASE

A 33-year-old morbidly obese (body mass index = 41 kg/m²) female with a history of chronic low back pain and posterior spinal fusion 5 years previously with the insertion of a fusion cage presented with sensory dysesthesias and paresthesias in the right anterolateral thigh, consistent with meralgia paresthetica. Symptoms included severe burning and tingling dysesthesia in the distribution of the LFCN. Hip extension and ambulation exacerbated these symptoms.

Lumbar magnetic resonance imaging demonstrated degenerative disc disease at the L3-L4 and L4-L5 levels, mild posterior disc bulging at the L5 and S1 levels, complete ankylosis at the L5-S1 level, and left foraminal narrowing at the L4-L5 level due to facet joint hypertrophy. The L3-L4 fused segments were stable. Although the patient's chronic back pain was relatively well controlled with pregabalin, celecoxib, and hydrocodone/APAP (10 mg/325mg; 6–8 tablets daily), her thigh pain was unresponsive to various treatment modalities. LFCN and fascia lata blocks using local anesthetic and steroids were performed at 2 different institutions over the past 3 years providing substantial pain relief; however, this pain relief was only temporary, lasting 2 weeks or less. At presentation, the patient rated her pain as 9/10 on a 0 to 10 numeric rating scale. Although the patient arrived at our clinic with a presumptive diagnosis of meralgia paresthetica, a physical examination revealed some atypical distribution of pain to the lateral thigh. Thus, a right iliotibial band block was performed to rule out iliotibial band bursitis. Only partial relief of symptoms was obtained. Although additional LFCN blocks with 5 mL bupivacaine 0.5% and methylprednisolone 40 mg were effective in providing complete relief of the right lateral thigh burning pain, this effect was only temporary. The patient expressed dissatisfaction with her treatments and requested "any" therapeutic intervention that might lead to long-lasting pain relief. At this time the known risks, benefits, and alternatives of pulsed radiofrequency neuromodulation of the LFCN were explained and the patient gave consent.

In the operating room, the patient was placed in the supine position and all ASA monitors were applied. The area above the anterior superior iliac spine (ASIS) was located fluoroscopically and the skin above was prepped with betadine and aseptically draped. A skin wheal was raised anterior and one centimeter medial and cephalad to the ASIS using 2 mL lidocaine 1%. Next, a disposable 20-gauge, 15 cm radiofrequency cannula (Model S-1510, NeuroTherm, Inc., Middleton, MA), with a 10 mm active tip was inserted to 12 cm (Fig. 1).

The introducer needle was withdrawn and the disposable RF electrode (Model RFDE-15, NeuroTherm, Inc., Middleton, MA) was advanced until seated firmly inside the cannula hub. This was accomplished without paresthesias or evidence of blood. Sensory stimulation using a NeuroTherm NT 1100 (NeuroTherm, Inc., Middleton, MA) radiofrequency generator showed

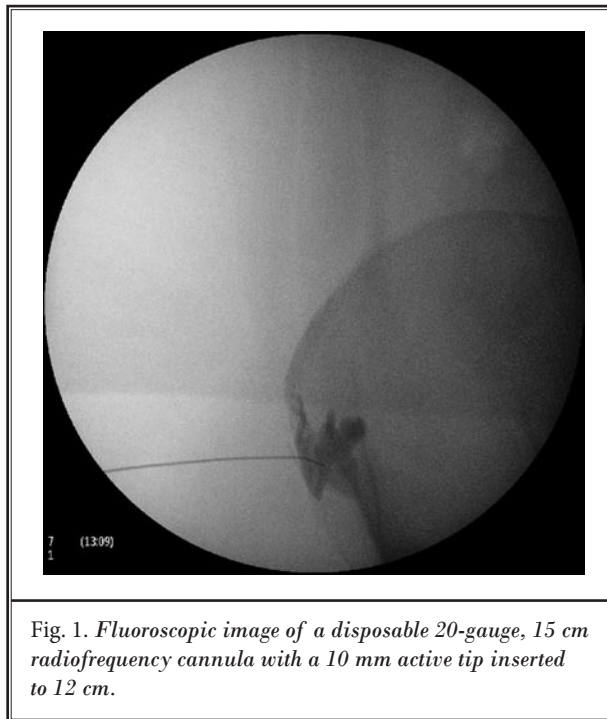


Fig. 1. Fluoroscopic image of a disposable 20-gauge, 15 cm radiofrequency cannula with a 10 mm active tip inserted to 12 cm.

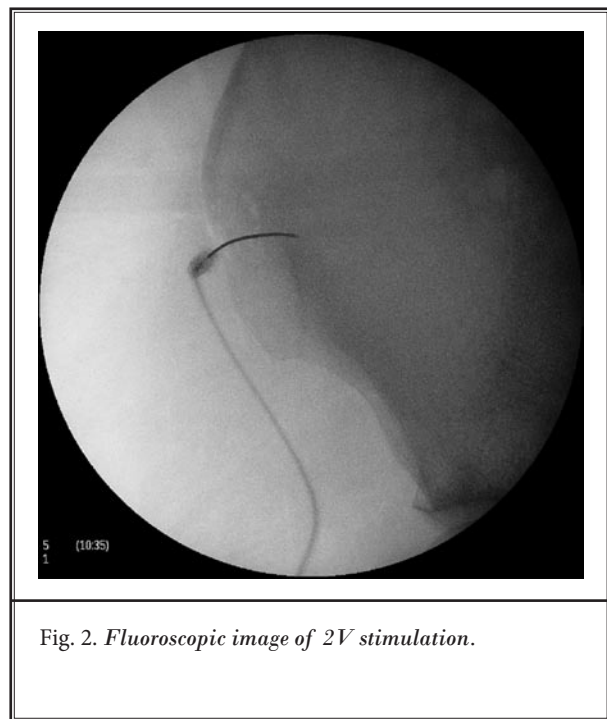


Fig. 2. Fluoroscopic image of 2V stimulation.

concordant pain in the right lateral thigh at 0.47 mA, which confirmed proper localization of the RF electrode. Motor stimulation was negative for movement of the right leg at 2 V (Fig. 2). Finally, pulsed radiofrequency was undertaken of the right LFCN elevating the temperature of the tissues to 42°C for a total of 120 seconds.

The patient reported that she felt the concordant stimulation to be equivalent to one of her worst burning dysesthesias in the affected area. After completion of the procedure, the RF electrode was removed and 1 mL of 0.5% bupivacaine and dexamethasone 4 mg were injected through the RF cannula. The cannula was then withdrawn and a sterile dressing was applied. During a 9-month follow-up, the patient reported no return of symptoms and expressed profound gratitude. The patient rated her pain as 0/10 on a 0 to 10 numeric rating scale. She was able to completely discontinue her use of hydrocodone, pregabalin, and celecoxib. She continues to exercise at home, and has also reduced 25 pounds since the procedure, due to her increased ability to be active.

DISCUSSION

We describe the first reported application of pulsed radiofrequency for the treatment of long-standing meralgia paresthetic pain. During a period of 3 years, the patient had experienced pain that was recalcitrant to conservative/pharmacologic therapy. Multiple LFCN blocks with local steroid applications had provided outstanding, albeit temporary pain relief. The patient was discouraged with the lack of success of her previous therapy and was referred to our clinic seeking a mode of treatment offering more prolonged or permanent pain relief. Physical examination and history uncovered multiple risk factors consistent with the diagnosis of meralgia paresthetica. These included morbid obesity (13) and a posterior lumbar spinal fusion procedure performed 5 years earlier, with a harvesting of bone material from the right iliac crest (14,15). Diagnostic nerve blocks performed in our clinic confirmed the diagnosis of meralgia paresthetica. Potential treatment modalities included peripheral nerve or spinal cord stimulation, cryo or radiofrequency lesioning, chemical or surgical neurolysis, or surgical nerve transaction (2,16-18).

We recommended pulsed radiofrequency to the patient for several reasons. First, the temporary effectiveness of the diagnostic and therapeutic blocks gave us confidence that the LFCN was the source of pain and required neuromodulation. Second, our previous experience using pulsed radiofrequency on medial branch nerves and published reports of its successful application in conditions involving nerve entrapment or compressive syndromes in other locations, i.e., ilioinguinal neuropathy (19) and carpal tunnel syndrome (20), suggested that similar therapeutic success might be achievable in meralgia paresthetica. Third, reports of anatomical variations in the course and localization of the LFCN and the proximity of the LFCN to the femoral and obturator nerves (21,22) suggested an increased risk of collateral damage if neuroablation was performed using continuous radiofrequency or chemical neurolysis. Finally, as a minimally invasive and relatively non-traumatic procedure, the use of pulsed radiofrequency would not cause nerve destruction or impair nerve function. Thus, its use would not preclude the eventual use of more aggressive treatment if pulsed radiofrequency failed to produce a satisfactory outcome. We informed the patient of 2 potential adverse side effects associated with the use of pulsed radiofrequency to treat meralgia paresthetica, i.e., persistent numbness and anesthesia dolorosa (23).

A single treatment with pulsed radiofrequency resulted in complete and sustained cessation of thigh pain in our patient with meralgia paresthetica. No side effects were evident. Following pulsed radiofrequency, bupivacaine and dexamethasone were administered prior to needle withdrawal. It is extremely unlikely that bupivacaine/dexamethasone contributed to long-term pain relief since the patient's symptoms had proved recalcitrant to prolonged pain relief to over 3 years of treatment which included multiple LFCN nerve blocks with and without steroid instillation, all performed with fluoroscopic guidance and injection of radiopaque contrast media. The patient eventually demonstrated an improvement in motor function in the treated leg. This outcome greatly enhanced the quality of life of the patient, who was able to exercise and lose 25 pounds over 6 months.

CONCLUSION

The case reported herein provides evidence that pulsed radiofrequency of the LFCN may offer an effective, low risk treatment in patients with meralgia paresthetica, who are refractory to conservative medical management or are unwilling or unfit to undergo surgery. Well-designed studies are required to evaluate whether this case is indicative of a unique and individual response or whether the results may be applicable to other meralgia paresthetica sufferers.

REFERENCES

1. Von Slobbe AM, Bohnen AM, Bernsen RMD, Koes BW, Bierma-Zeinstra SM. Incidence rates and determinants in meralgia paresthetica in general practice. *J Neurol* 2004; 251:294-297.
2. Khalil N, Nicotra A, Rakowicz W. Treatment for meralgia paresthetica (Review). *Cochrane Library* 2008; 4:1-15.
3. Malik K, Benzon HT. Radiofrequency applications to dorsal root ganglia. *Anesthesiology* 2008; 109:527-542.
4. Sluijter M, Racz G. Technical aspects of radiofrequency. *Pain Pract* 2002; 2:195-200.
5. Cahana A, Vutskits, L, Muller D. Acute differential modulation of synaptic transmission and cell survival during exposure to pulsed and continuous radiofrequency energy. *J Pain* 2003; 4:197-202.
6. Wu H, Groner J. Pulsed radiofrequency treatment of articular branches of the obturator and femoral nerves. *Pain Pract* 2007; 7:341-344.
7. Abejón D, Garcia-de3l-Valle S, Fuentes ML, Gómez-Arnau JI, Rieg E, van Zundert J. Pulsed radiofrequency in lumbar radicular pain: Clinical effects in various etiological groups. *Pain Pract* 2007; 7:21-26.
8. Balogh SE. Transcutaneous application of pulsed radiofrequency: Four case reports. *Pain Pract* 2004; 4:310-313.
9. Van Zundert J, Brabant S, Van de Kelft E, Vercruyssen A, Van Buyten JP. Pulsed radiofrequency treatment of the gasserian ganglion in patients with idiopathic trigeminal neuralgia. *Pain* 2003; 104:449-452.
10. Kim YH, Lee CJ, Lee SC, Huh J, Nahm FS, Kim ZH, Lee MK. Effect of pulsed radiofrequency for postherpetic neuralgia. *Acta Anaesthesiol Scand* 2008; 52:1140-1143.
11. Wilkes D, Ganceres N, Solanki D, Hayes M. Pulsed radiofrequency treatment of lower extremity phantom limb pain. *Clin J Pain* 2008; 24:736-739.
12. Cohen SP, Sireci A, Wu CL, Larkin TM, Williams KA, Hurley RW. Pulsed radiofrequency of the dorsal root ganglia is superior to pharmacotherapy or pulsed radiofrequency of the intercostal nerves in the treatment of chronic postsurgical thoracic pain. *Pain Physician* 2006; 9:227-235.
13. Mondelli M, Rossi S, Romano C. Body mass index in meralgia paresthetica: A case-control study. *Acta Neurol Scand* 2007; 116:118-122.
14. Mirovsky Y, Neuwirth M. Injuries to the lateral femoral cutaneous nerve during spine surgery. *Spine* 2000; 25:1266-1269.
15. van den Broecke DG, Schuurman AH, Borg EDH, Kon M. Neurotomesis of the

- lateral cutaneous nerve when coring for iliac crest bone graft. *Plastic Reconstruct Surg* 1998; 102:1163-1166.
16. Barna SA, Hu MM, Buxo C, Trella J, Cosgrove GR. Spinal cord stimulation for treatment of meralgia paresthetica. *Pain Physician* 2005; 8:315-318.
 17. Siu TL, Chandran KN. Neurolysis for meralgia paresthetica: An operative series of 45 cases. *Surg Neurol* 2005; 63:19-23.
 18. van Eerten PV, Polder TW, Broere CAJ. Operative treatment of meralgia paresthetica: Transaction versus neurolysis. *Neurosurgery* 2005; 37:63-65.
 19. Mitra R, Zeighami A, Mackey S. Pulsed radiofrequency for the treatment of chronic ilioinguinal neuropathy. *Hernia* 2007; 11:369-371.
 20. Haider N, Mekasha D, Chiravuri S, Wasserman R. Pulsed radiofrequency of the median nerve under ultrasound guidance. *Pain Physician* 2007; 10:765-770.
 21. Aszmann OC, Dellon ES, Dellon AL. Anatomical course of the lateral femoral cutaneous nerve and its susceptibility to compression and injury. *Plastic Reconstruct Surg* 1997; 100:500-504.
 22. de Ridder VA, de Lange S, Popta JV. Anatomical variations of the lateral cutaneous nerve and the consequences of surgery. *J Orthop Trauma* 1999; 13:207-211.
 23. Kanpolat Y, Savas A, Bekar A, Berk C. Percutaneous controlled radiofrequency trigeminal rhizotomy for the treatment of idiopathic trigeminal neuralgia: 25-year experience with 1600 patients. *Neurosurgery* 2001; 48:524-534.

