

# Adhesive arachnoiditis following lumbar epidural steroid injections: a report of two cases and review of the literature

Elon Eisenberg<sup>1,2</sup>  
Rephael Goldman<sup>3</sup>  
Dorit Schlag-Eisenberg<sup>4</sup>  
Anat Grinfeld<sup>5</sup>

<sup>1</sup>Pain Research Unit, Institute of Pain Medicine, Rambam Health Care Campus, Haifa, Israel; <sup>2</sup>B. Rappaport Faculty of Medicine, Technion – Israel Institute of Technology, Haifa, Israel; <sup>3</sup>Amitim Clinic, Haifa, Israel; <sup>4</sup>Department of Medical Imaging, Carmel Medical Center, Haifa, Israel; <sup>5</sup>Department of Medical Imaging, Rambam Health Care Campus, Haifa, Israel

**Abstract:** Lumbar epidural steroid injections (LESIs) are commonly used for managing lower back pain (LBP) and radicular pain. LESIs are generally considered safe with only rare serious complication. One very rare complication that is frequently cited in the literature is adhesive arachnoiditis. However, a literature search failed to detect even one published manuscript, clearly documenting LESI induced arachnoiditis. This article presents two patients who received a transforaminal L5–S1 and two L3–L4 interlaminar LESIs. Although the presented patients developed clear radiological (MRI) findings of arachnoiditis, they were not accompanied by any improvement or deterioration in their clinical condition. The article also reviews the literature on the prevalence, pathogenesis, diagnosis, and clinical features of adhesive arachnoiditis. Literature suggests that adhesive arachnoiditis following LESIs is a rare entity, which – as seen in our patients – has clear radiological characteristics but uncertain pathogenesis. It has a large spectrum of clinical presentation, ranging from an incidental finding to a serious neurological sequela. In at least some patients with adhesive arachnoiditis following LESI, the radiological and clinical findings may fail to correlate with each other. In light of the fact that LESI is one of the most commonly performed procedures for managing LBP, clinicians should be aware of this rare yet existing entity.

**Keywords:** sciatica, spinal stenosis, magnetic resonance imaging, MRI, radicular pain

## Introduction

Lower back pain (LBP) with a radicular component remains a significant health problem affecting millions of people worldwide.<sup>1</sup> Treatment options include conservative therapies, interventions, and surgery. Lumbar epidural steroid injections (LESIs) are one of the most commonly utilized interventions for managing LBP and radicular pain.<sup>2</sup> LESIs deliver steroids into the epidural space, in the aim to reduce inflammation around – and/or compression on – lumbar nerve roots.<sup>3</sup> Technically, they are performed under fluoroscopic guidance via interlaminar, transforaminal, or caudal approaches; each has advantages and disadvantages.<sup>4</sup> Regardless of the approach used, LESIs are generally considered as relatively safe procedures. The most common complications are related to either inaccurate needle placement or adverse reaction to injected medicines. Symptoms include headache, soreness at the injection site, and transient toxicity. Seldom, more serious complication may occur such as hemorrhage, infection, trauma to a nerve root, or paraplegia due to arterial occlusion associated with injection of particulate steroids.<sup>4–6</sup> In 2014 the Food and Drug Administration (FDA) issued a

Correspondence: Elon Eisenberg  
Pain Research Unit, Institute of Pain  
Medicine, Rambam Health Care Campus,  
PO Box 9602, Haifa 3109601, Israel  
Tel +972 4 777 2234  
Fax +972 4 777 3505  
Email e\_eisenberg@rmc.gov.il

briefing document on ESIs, which included cases of serious neurologic adverse events caused by arachnoiditis.<sup>7</sup> Although the published medical literature on the use of ESI is extensive, it does not provide sufficient details on the frequency, pathogenesis, and clinical features of adhesive arachnoiditis.

In this manuscript, we report on two patients who developed arachnoiditis following LESIs and review the relevant literature on this condition.

## Case reports

Written informed consent has been provided by the patients to have their case details and accompanying images published. Institutional approval was not required to publish the case details.

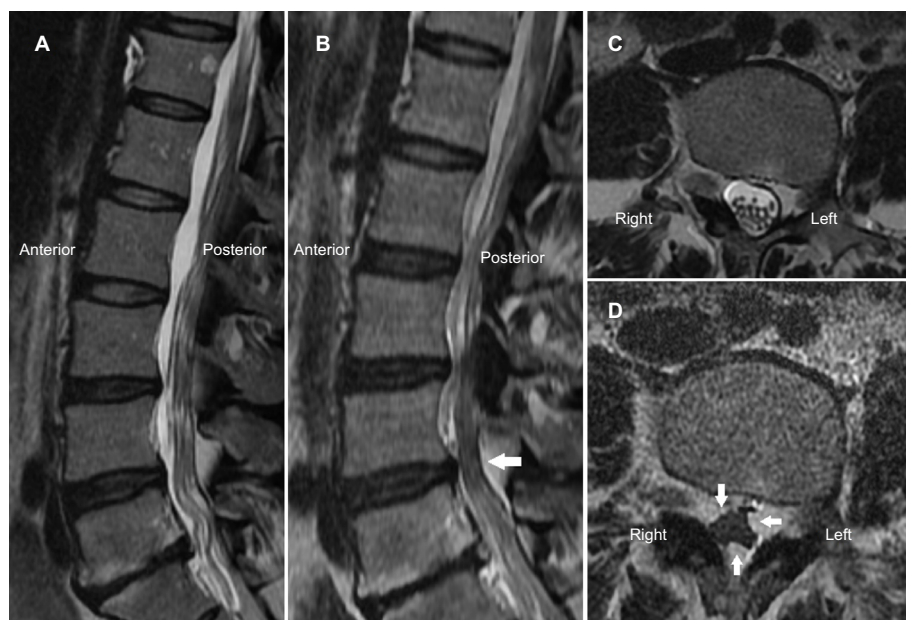### Case I

**History:** A 41-year-old, otherwise healthy woman has had a 16-year history of LBP and bilateral leg pain, worse on the left side. Her pain began a few years prior to a motor vehicle accident in 2009, which subsequently worsened her condition. She was treated intermittently at different pain clinics by multiple medical, physical, and complementary therapies with no obvious relief. Due to prominent left sciatica, she was referred to another institution for a transforaminal block at the level of L5–S1 on the left side.

**Procedure:** The following protocol was performed on March 2014. The patient was placed in prone position. A straight sharp 22 G needle was inserted into the left L5–S1 foramen under fluoroscopic guidance. An unmentioned volume of iopamiro 300 mg/mL (Iopamiro 300™; Rafa Laboratories, Ltd., Jerusalem, Israel) was injected and reportedly distributed along the L5 nerve root. No vascular spread or cerebrospinal fluid (CSF) return was noticed. Forty milligrams (1 mL) of methylprednisolone (Depomedrol™; Pfizer, Puurs, Belgium) and 3 mL of lidocaine 2% (Rafa Laboratories, Ltd.) were subsequently injected. The procedure was reported by the patient as “very painful”, but was otherwise uneventful.

**Outcome:** The procedure did not result in any improvement (or worsening) in her symptoms. She failed to improve after several other noninvasive therapies and was eventually referred to a spine surgeon who ordered a second MRI study.

**MRI studies:** The first MRI study was performed in October 2013 (Figure 1A, C). T2W sagittal and axial sections demonstrated L5–S1 discopathy with a left paramedian disc protrusion. Discrete cauda equine nerve roots were easily identified on both sagittal and axial sections. The second MRI was performed in August 2017 (Figure 1B, D). No major changes were demonstrated in the degenerative findings or the herniated disc. However, sagittal sections showed clumping



**Figure 1** T2W Sagittal and axial MRI studies of patient I.

**Notes:** Sagittal MRI studies before the ESI (A) showing discrete cauda equine nerve roots, and after the ESI (B) showing clumping of the nerve roots, mainly at the L4–L5 level (arrow). Axial study before the injection (C) shows a more or less symmetrical distribution of the nerve roots at the L4–L5 level, whereas after the injection (D), the caudal nerve roots create a mass-like structure in the center of the spinal canal (arrows) with no surrounding CSF.

**Abbreviations:** CSF, cerebrospinal fluid; ESI, epidural steroid injection.

of the nerve roots, mainly at the L4–L5 level (one level above the transforaminal injection). Axial sections showed a cluster of the caudal nerve roots creating a mass-like structure in the center of the spinal canal. No surrounding CSF could be seen at that level, indicating adhesions of the thecal sac to the clumped nerve roots.

## Case 2

**History:** A 76-year-old woman was referred to our institution for LESI injections as part of managing chronic LBP. Her pain radiated down her posterior thighs bilaterally, mainly while ambulating and was consistent with “spinal claudication”. Her walking distance was limited to <100 m. She has had this pain for 3 years despite analgesic treatments. A spine surgeon did not recommend surgery due to the diffuse nature of the degenerative changes throughout the lumbar spine. Her past medical history included hypertension, myocardial infarction in 2008, dyspepsia, and right knee arthroplasty in 2010.

**Procedure:** The patient received two L3–L4 interlaminar LESIs in May and July 2016, both in prone position and under fluoroscopic guidance. Needle tip position in the epidural space was verified by injecting 0.5–1.5 mL of the contrast media iohexol (Omnipaque™ 300 mg/mL; GE Healthcare, Nydalen, Norway). The epidural space was clearly demonstrated with no vascular or intrathecal spread of the contrast media. Eighty milligrams of methylprednisolone, 30 mg lidocaine, and 2 mL NaCl at a total volume of 7 mL were

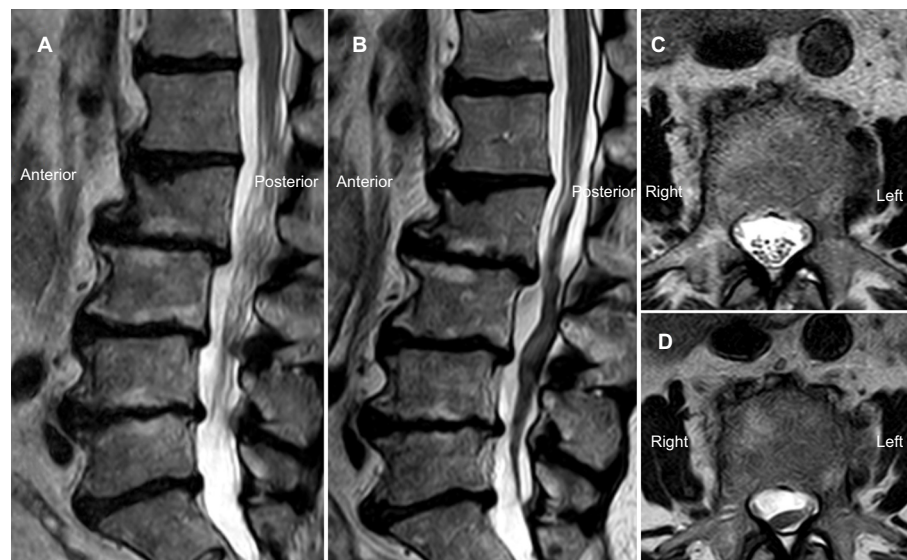
injected. Neither CSF or blood return nor paresthesia was noted during both procedures.

**Outcome:** No change (improvement or deterioration) in symptoms was reported following the injections. She was referred to a second MRI scan in December 2017 for reevaluation of her condition.

**MRI studies:** The first MRI study was performed in October 2015 (Figure 2A, C). T2W sagittal sections showed degenerative disc and endplate changes at all lumbar spaces, L2–L3 spondylolisthesis, and moderate spinal stenosis at L3–L4 and L4–L5 levels. Discrete cauda equine nerve roots could be identified on both sagittal and axial images. A second MRI was performed in December 2017 (Figure 2B, D). No major changes in the degenerative findings were noted. However, the cauda equine nerve roots were clumped together and created a single elongated structure throughout the entire lumbar spinal canal. Axial sections showed a cluster of the caudal nerve roots displaced posteriorly and to the left.

## Discussion Prevalence

Adhesive arachnoiditis is apparently a rare entity. Only 41 cases were identified by the FDA, with the majority submitted to the FDA by costumers.<sup>7,8</sup> Although frequently cited in the ESI literature, a literature search failed to detect even one published case report of clearly documented ESI-induced arachnoiditis. The cases presented here seem to be



**Figure 2** T2W Sagittal and axial MRI studies of patient 2.

**Notes:** Sagittal MRI studies of patient 2 before the ESI (A) showing discrete cauda equine nerve roots along the entire lumbar spine. After the ESI (B), clumped nerve roots create an elongated single mass, mimicking “tethered cord” along the entire lumbar spine. Axial MRI study before the injection (C) shows symmetrical distribution of the nerve roots at L3 level. After the injection (D), the caudal nerve roots form a mass displaced posteriorly and to the left.

**Abbreviation:** ESI, epidural steroid injection.

the first reports of arachnoiditis following transforaminal and interlaminar LESIs. One exception is a case report of a patient who underwent caudal ESI for lumbar radiculopathy and developed arachnoiditis, presented by progressive neurological abnormalities a few days following the injection. However, an MRI scan and laboratory tests were consistent with infectious arachnoiditis, which required antibiotic treatment.<sup>9</sup> As mentioned earlier, the procedures in our patients were uneventful and no suspicion of postprocedure infection was raised.

## Pathogenesis

A large spectrum of insulting events leading to adhesive arachnoiditis have been reported in the literature, including lumbar spine surgery (especially if repeated multiple times), history of contrast myelography in past decades, hemorrhage or infection within the spinal canal, and spinal anesthesia.<sup>10–13</sup> Following the insulting event, the pia–arachnoid undergoes an inflammatory reaction to an injurious stimulus, leading to intrathecal scarring and resulting in tethering and clumping of neural elements.<sup>10</sup>

Factors that may cause arachnoiditis following LESI include hemorrhage, infection, or direct neural injury. Other possible factors are the injected substances. Four potential causative materials were used during the procedures in our patients; three of them were deliberately injected: local anesthetics, steroids, and contrast materials. The fourth, antiseptic materials used for skin preparation prior to the procedure, might have accidentally entered into the spinal canal.

Local anesthetics, including lidocaine, have been proposed as a cause of adhesive arachnoiditis mainly due to their neural toxicity especially at high concentrations.<sup>14,15</sup> However, animal studies do not support this hypothesis.<sup>16</sup> Moreover, the low injected doses in our patients, which consisted of 30 mg in each injection, is not very likely to be the cause.

Steroids are the next conceivable neurotoxic compound. Methylprednisolone acetate, one of the most commonly used steroids injected during LESIs, contains polyethylene glycol. If injected intraspinally, sterile meningitis and arachnoiditis may occur.<sup>17</sup> Apparently, the epidural space is not totally separate from the subdural and/or subarachnoid space. Many thousands of arachnoid villi subtend all the membranes from the intrathecal space, and many of these end in the large epidural veins. Therefore, the various spaces and membranes are not only contiguous, but continuous. Hence, an injection of methylprednisolone acetate into the epidural space may spread to the arachnoid space.<sup>17</sup> Recent studies in animals yielded conflicting results: one study in dogs showed evidence

for pia, arachnoid, and dura matter adhesion and nerve roots fibrosis following intrathecal methylprednisolone injection,<sup>18</sup> whereas another study in pigs found similar manifestations following epidural injection of methylprednisolone acetate.<sup>19</sup> Of interest is an extensive Japanese study, in which four intrathecal injections of methylprednisolone were administered for the management of postherpetic neuralgia, with no reported complications.<sup>20</sup> The US FDA report states that: “41 cases of arachnoiditis reported after ESI did not provide sufficient clinical detail to make a reasonable assessment regarding causality”. Yet, in 39 cases “particulate” corticosteroid injection was reported.<sup>7</sup> In our patients, the particulate corticosteroid Depomedrol™ was injected; however, its causative contribution to the formation of the arachnoiditis remains controversial.

Contrast medium such as iophendylate was used for myelography decades ago and is a suspected underlying causative factor for arachnoiditis.<sup>21</sup> Nowadays, modern, water-soluble, nonionic contrast media such as iopamiro, which was used in our first patient and iohexolin in the second, are generally considered safe for both epidural and intrathecal injections,<sup>22</sup> even though a general warnings was issued by FDA that iohexol as contrast media may have serious adverse reactions, including arachnoiditis.<sup>23</sup>

Antiseptic materials: We have not been able to obtain information about the specific antiseptic materials that were used for skin preparation in our patients. Presumably it has been chlorhexidine, which is used routinely for this purpose in our country/had most likely been used. Limited case report-based information is available on chlorhexidine risk of neurotoxicity. In some of them, a much larger quantity of chlorhexidine than is routinely used for skin disinfection was mistakenly injected into the spinal canal and led to chronic adhesive arachnoiditis with progressive neurological deterioration.<sup>24</sup> Recent guidelines from Great Britain and Ireland recommend the use of chlorhexidine in alcohol for skin antisepsis before performing central neuroaxial blockade, while taking meticulous measures to prevent chlorhexidine from reaching the CSF.<sup>24</sup>

Interestingly, our first patient received transforaminal LESI with only limited spread of the injected drugs in the epidural space, developed relatively localized arachnoiditis, whereas the second patient, who received interlaminar injection with more diffuse epidural spread and developed arachnoiditis along the entire lumbar spine. This seems to support the possibility that the injected substances served as a causative factor. Lastly, the possibility that arachnoiditis can result from degenerative spine disease (thus, unrelated to the

ESI) has been raised more than two decades ago,<sup>25</sup> but never received any further support in the literature since then. The fact that the degenerative spine disease is so common and arachnoiditis and, on the other hand, is so rare, makes this possibility unrealistic.

## Diagnosis

Arachnoiditis is primarily a radiological diagnosis, which is based on the following MRI criteria: 1) conglomerations of adherent nerve roots residing centrally within the thecal sac; 2) nerve roots adherent peripherally giving the impression of an “empty sac”; 3) soft tissue mass replacing the subarachnoid space.<sup>26</sup> Accordingly, the MRI scans of our two patients, which showed conglomerations of adherent nerve roots and clumped nerve roots creating a mass replacing the subarachnoid space (in the second patient), were consistent with these diagnostic criteria.

## Clinical features

The clinical presentation of arachnoiditis can be highly variable: symptoms and signs may range from back pain with or without unilateral or bilateral leg pain to severe sensory motor and autonomic impairments.<sup>10,11</sup> In our patients, no new accompanying clinical symptoms or signs were identified following the procedure. Yet, the possibility that the arachnoiditis might have contributed to the persistency of their symptoms cannot be ruled out. A related feature of arachnoiditis is an inconsistency between radiological and clinical findings. One possible explanation for this clinical–radiological discrepancy is a substantially variable delay of weeks, years, or even a decade between the putative insulting event and the onset of clinical findings, which is well documented.<sup>10,11</sup> Thus, it is possible that the radiological findings precede the clinical once considerably.

One possible limitation of this report is the fact that the follow-up MRIs of our patients were performed 1.5–3 years after the procedures. As this is a relatively long time, the temporal relationship with the MRI changes following the LESI points to but does not necessarily imply a causal relationship between them. At the same time, we cannot identify any other causative factor, which may better explain the formation of arachnoiditis at the injection sites.

## Summary

The presented patients and the reviewed literature suggest that: 1) adhesive arachnoiditis following LESIs has a large spectrum of clinical presentation, ranging from a serious complication to an incidental finding; 2) the radiological

and the clinical findings may fail to correlate with each other in at least in some patients with adhesive arachnoiditis; 3) clinicians should be aware of this rare yet existing entity, especially since LESI is one of the most commonly performed procedures for managing LBP.

## Disclosure

The authors report no conflicts of interest in this work.

## References

- Hoy D, Bain C, Williams G, et al. A systematic review of the global prevalence of low back pain. *Arthritis Rheum*. 2012;64(6):2028–2037.
- Manchikanti L, Pampati V, Falco FJ, Hirsch JA. Growth of spinal interventional pain management techniques: analysis of utilization trends and Medicare expenditures 2000 to 2008. *Spine (Phila Pa 1976)*. 2013;38(2):157–168.
- Ackerman WE, Ahmad M. The efficacy of lumbar epidural steroid injections in patients with lumbar disc herniations. *Anesth Analg*. 2007;104(5):1217–1222.
- Liu J, Zhou H, Lu L, et al. The effectiveness of Transforaminal versus caudal routes for epidural steroid injections in managing lumbosacral radicular pain: a systematic review and meta-analysis. *Medicine (Baltimore)*. 2016;95(18):e3373.
- Bicket MC, Chakravarthy K, Chang D, Cohen SP. Epidural steroid injections: an updated review on recent trends in safety and complications. *Pain Manag*. 2015;5(2):129–146.
- Makkar JK, Singh PM, Jain D, Goudra B. Particulate vs non-particulate steroids for transforaminal epidural steroid injections: systematic review and meta-analysis of the current literature. *Pain Physician*. 2016;19(6):327–340.
- US FDA [homepage on the Internet]. Anesthetic and Analgesic Drug Products Advisory Committee Meeting. November 24–25, 2014. Epidural steroid injections (ESI) and the risk of serious neurologic adverse reactions. Available from: <https://www.pharmamedtechbi.com/~media/Supporting%20Documents/The%20Pink%20Sheet%20DAILY/2014/November/112114%20FDA%20edpidural%20adcom%20background.pdf>. Accessed January 21, 2019.
- Manchikanti L, Benyamin RM. Key safety considerations when administering epidural steroid injections. *Pain Manag*. 2015;5(4):261–272.
- Nanjayan SK, Swamy GN, Yallappa S, Bommireddy R. Arachnoiditis following caudal epidural injections for the lumbo-sacral radicular pain. *Asian Spine J*. 2013;7(4):355–358.
- Killeen T, Kamat A, Walsh D, Parker A, Aliashkevich A. Severe adhesive arachnoiditis resulting in progressive paraplegia following obstetric spinal anaesthesia: a case report and review. *Anaesthesia*. 2012;67(12):1386–1394.
- Guyer DW, Wiltse LL, Eskay ML, Guyer BH. The long-range prognosis of arachnoiditis. *Spine (Phila Pa 1976)*. 1989;14(12):1332–1341.
- Koerts G, Rooijackers H, Abu-Serieh B, Cosnard G, Raftopoulos C. Postoperative spinal adhesive arachnoiditis presenting with hydrocephalus and cauda equina syndrome. *Clin Neurol Neurosurg*. 2008;110(2):171–175.
- Hewson DW, Bedford NM, Hardman JG. Spinal cord injury arising in anaesthesia practice. *Anaesthesia*. 2018;73(Suppl 1):43–50.
- Lambert LA, Lambert DH, Strichartz GR. Irreversible conduction block in isolated nerve by high concentrations of local anesthetics. *Anesthesiology*. 1994;80(5):1082–1093.
- Hampel K, Steinfeldt T, Wulf H. Spinal anesthesia revisited: toxicity of new and old drugs and compounds. *Curr Opin Anaesthesiol*. 2014;27(5):549–555.
- Nguyen C, Ho KC, Haughton VM. Effect of lidocaine on the meninges in an experimental animal model. *Invest Radiol*. 1991;26(8):745–747.
- Nelson DA. Dangers from methylprednisolone acetate therapy by intraspinal injection. *Arch Neurol*. 1988;45(7):804–806.

18. Lima RM, Navarro LH, Carness JM, et al. Clinical and histological effects of the intrathecal administration of methylprednisolone in dogs. *Pain Physician*. 2010;13(5):493–501.
19. Kitsou MC, Kostopanagiotou G, Kalimeris K, et al. Histopathological alterations after single epidural injection of ropivacaine, methylprednisolone acetate, or contrast material in swine. *Cardiovasc Intervent Radiol*. 2011;34(6):1288–1295.
20. Kotani N, Kushikata T, Hashimoto H, et al. Intrathecal methylprednisolone for intractable postherpetic neuralgia. *N Engl J Med*. 2000;343(21):1514–1519.
21. Anderson TL, Morris JM, Wald JT, Kotsenas AL. Imaging appearance of advanced chronic adhesive arachnoiditis: a retrospective review. *AJR Am J Roentgenol*. 2017;209(3):648–655.
22. Pomerantz SR. Myelography: modern technique and indications. *Handb Clin Neurol*. 2016;135:193–208.
23. OMNIPAQUE™ (iohexol) Injection 140 180 240 300 350. FDA Reference ID: 4080358. Available from: [https://www.accessdata.fda.gov/drugsatfda\\_docs/label/2017/018956s099lbl.pdf](https://www.accessdata.fda.gov/drugsatfda_docs/label/2017/018956s099lbl.pdf). Accessed January 21, 2019.
24. Association of Anaesthetists of Great Britain and Ireland, Obstetric Anaesthetists' Association; Regional Anaesthesia UK; Association of Paediatric Anaesthetists of Great Britain and Ireland, et al. Safety guideline: skin antisepsis for central neuraxial blockade. *Anaesthesia*. 2014; 69(11):1279–1286.
25. Jackson A, Isherwood I. Does degenerative disease of the lumbar spine cause arachnoiditis? A magnetic resonance study and review of the literature. *Br J Radiol*. 1994;67(801):840–847.
26. Ross JS, Masaryk TJ, Modic MT, et al. MR imaging of lumbar arachnoiditis. *AJR Am J Roentgenol*. 1987;149(5):1025–1032.

## Journal of Pain Research

### Publish your work in this journal

The Journal of Pain Research is an international, peer reviewed, open access, online journal that welcomes laboratory and clinical findings in the fields of pain research and the prevention and management of pain. Original research, reviews, symposium reports, hypothesis formation and commentaries are all considered for publication.

Submit your manuscript here: <https://www.dovepress.com/journal-of-pain-research-journal>

Dovepress

The manuscript management system is completely online and includes a very quick and fair peer-review system, which is all easy to use. Visit <http://www.dovepress.com/testimonials.php> to read real quotes from published authors.